

Pentalogy of Fallot

Sunil Mhaske*, Ramesh B. Kothari**, Sandeep Deokate***, Ram Sethi***, Pavan Suryawanshi***, Nishad Patil***, Rahul Maski***, Niverti Mundhe***, Sheetal Kedar ****

Authors affiliation

*Professor & Head Dept of Paediatrics **Assistant Professor
*** Residents ****Intern, Dept of Paediatrics; Padmashree Dr. Vithalrao Vikhe Patil Medical College & Hospital, Near Govt. Milk Dairy, Vilad Ghat, Ahmednagar - 414111.

Reprints requests

Sunil Mhaske, Professor & Head, Dept of Paediatrics; Padmashree Dr. Vithalrao Vikhe Patil Medical College & Hospital, Near Govt. Milk Dairy, Vilad Ghat, Ahmednagar - 414111.
E-mail: sunilmhaske1970@gmail.com

Abstract

The pentalogy of Fallot is a variant of the more common tetralogy of Fallot, comprising the classical four features with the addition of an atrial septal defect or patent ductus arteriosus.

The five features therefore are: 1. Ventricular septal defect (VSD), 2. Right ventricular outflow tract narrowing or complete obstruction, 3. Right ventricular hypertrophy, 4. Overriding aorta and 5. Atrial septal defect (ASD).

Keywords: Pentalogy of Fallot; VSD; Right Ventricular Outflow Tract Narrowing; Right Ventricular Hypertrophy; Overriding Aorta; ASD.

Introduction

Tetralogy of Fallot, also known as Fallot's syndrome or Fallot's tetrad, has four key features. A ventricular septal defect (a hole between the ventricles) and many levels of obstruction from the right ventricle to the lungs (pulmonary stenosis) are the most important. Also, the aorta (major artery from the heart to the body) lies directly over the ventricular septal defect, and the right ventricle develops thickened muscle. Because the aorta overrides the ventricular defect and there is pulmonary stenosis, blood from both ventricles (oxygen-rich and oxygen-poor) is pumped into the body. Sometimes the pulmonary valve is completely obstructed (pulmonary atresia). Infants and young children with unrepaired tetralogy of Fallot are often blue (cyanotic) as in the present case. The reason is that some oxygen-poor blood is pumped to the body. When the above condition is associated with atrial septal defect, it is called Pentalogy of Fallot.

Case summary

10 years girl was admitted in our hospital with complaints of breathlessness, palpitation since 3

years. Her symptoms aggravated over exertion and got relieved by rest. She was having history of recurrent respiratory tract infections since she was 3 years of age. She was having history of bluish discoloration of tongue, nail beds since last 7 years. She had been treated for her previous illnesses by local practitioner by symptomatic treatment. Her parents had family history of non-consanguineous marriage. She was a full term normal hospital delivery with good cry and adequate weight at birth. Our case was first issue of parents out of their 3 siblings (2 females and a male); none of them having any congenital anomaly or similar illness. We admitted the girl to our hospital in paediatric ward for further investigations and management.

On examination, her pulse was 84beats/minute and blood pressure was 100/66mmHg. Clubbing and central cyanosis were present. On examination of cardiovascular system, she was having pansystolic murmur. The murmur was prominent over left parasternal, mitral and aortic areas. No parasternal thrill was present All other systemic examinations were within normal limits.

Her investigations were as follows:

Hb: 14.1gm%

TLC: 8500/cmm
 P- 37, L- 57, E- 05, M- 01, B- 00
 Platelet count: 2.32lacs/cmm.
 ESR: 12mm at end of 1st hr.
 ECG revealed right ventricular hypertrophy.
 Chest X-ray showed boot shaped heart with cardiomegaly.

2D ECHO and Color Doppler of heart state presence of a ventricular septal defect of 12mm diameter with right to left shunt, atrial septal defect of 5mm diameter with left to right shunt, presence of overriding of aorta and reduced pulmonary blood flow due to narrowing of pulmonary valve. There was evidence of right ventricular hypertrophy (RV wall thickness -18mm)

Fig. 1: Case of Pentalogy of Fallot

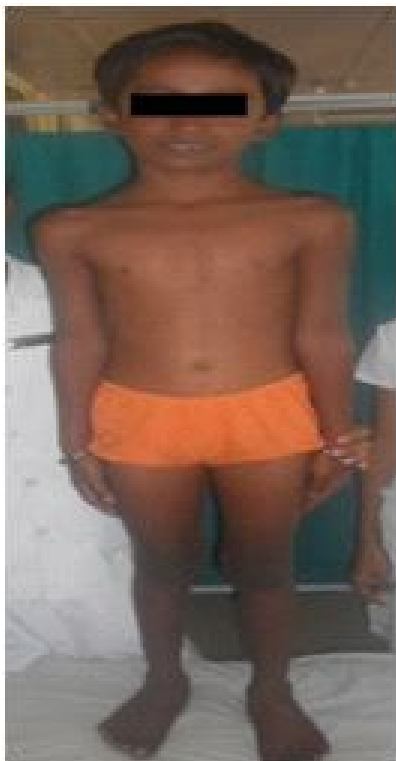

Fig. 2: Cyanosis of lips

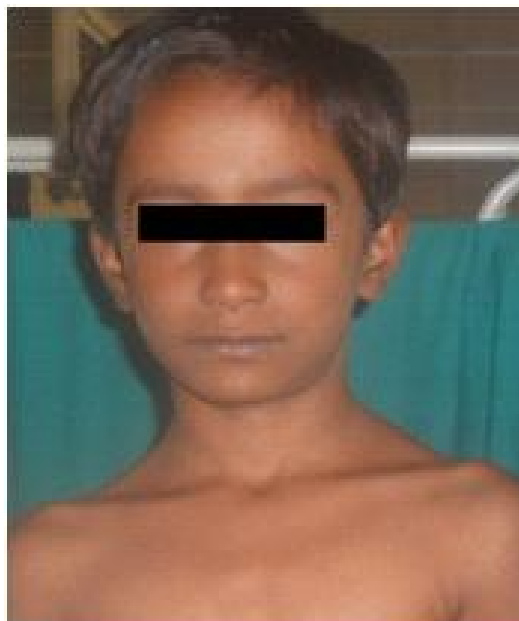

Fig. 4: X-ray chest showing boot shaped heart with cardiomegaly

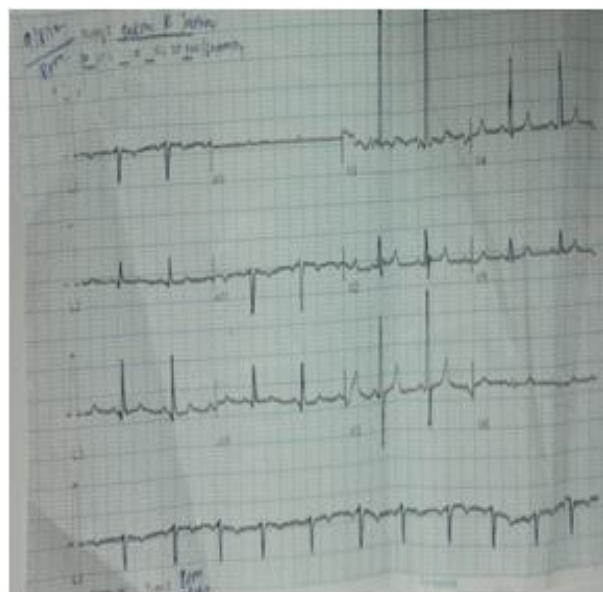
Fig. 3: Cyanosis of tongue

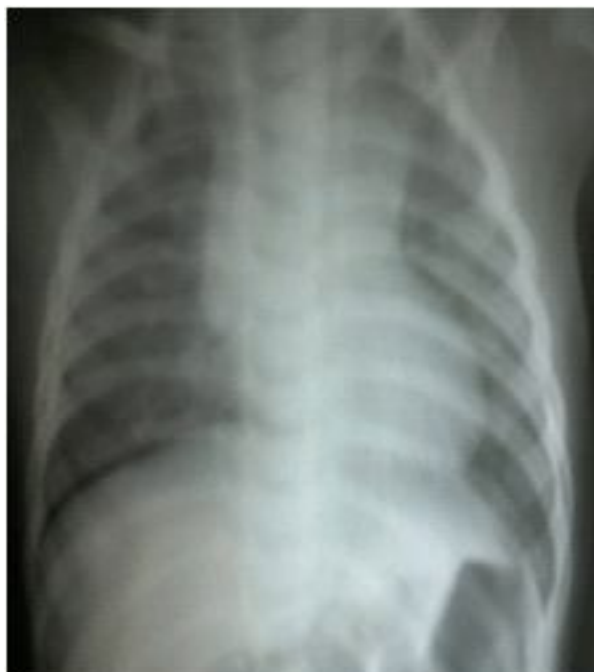

Fig. 5: 2D-ECHO report

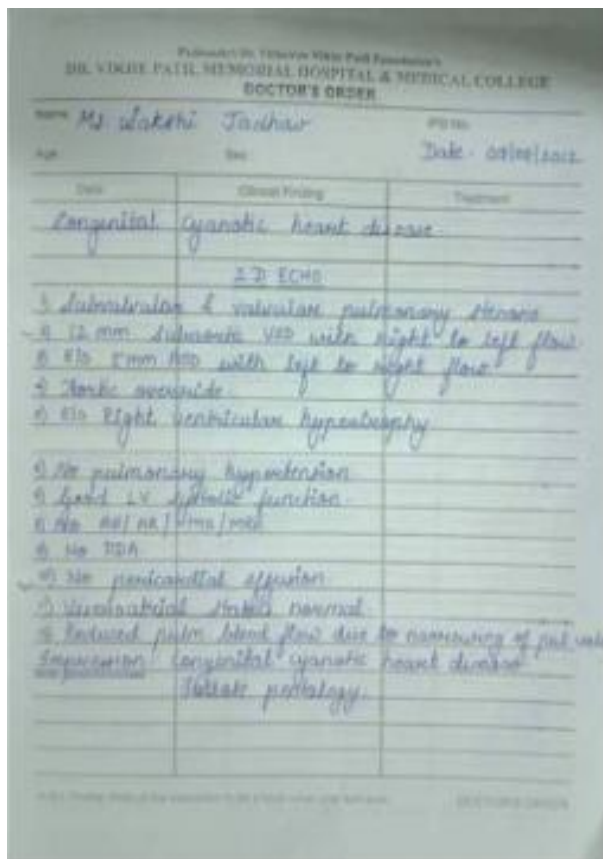

Fig. 6: ECG showing right ventricular hypertrophy.



Discussion

Tetralogy of Fallot (TOF) is the most common cyanotic congenital heart disease in children but occurs rarely in adults. Its etiology is still not clear

but its embryogenesis involves anterior deviation of the septal insertion of the infundibular ventricular septum resulting in mal-alignment of the outlet septum, ventricular septal deviation (VSD), pulmonary outflow tract stenosis and aortic override. In addition, right ventricular hypertrophy is noted secondary to pulmonary stenosis.

Clinical presentation consists of cyanosis, clubbing of the fingers, polycythemia and exertional dyspnea. Cyanosis and polycythemia may be noted in the newborn. The extent of cyanosis depends on the balance of systemic and pulmonary vascular resistance, which depends on the severity of right ventricular outlet obstruction. The more severe the obstruction, the more blood flows into the left side. Therefore, the more severe the pulmonary stenosis, the more protection from lung disease is noted. Mild pulmonary stenosis may present with mild cyanosis or even acyanosis, termed pink TOF or acyanotic TOF. Patients with this condition may have lung disease and may expire in early childhood if no repair or palliative surgery is performed.

Signs and symptoms

Tetralogy of Fallot results in low oxygenation of blood due to the mixing of oxygenated and deoxygenated blood in the left ventricle via the VSD and preferential flow of the mixed blood from both ventricles through the aorta because of the obstruction to flow through the pulmonary valve. This is known as a right-to-left shunt. The primary symptom is low blood oxygen saturation with or without cyanosis from birth or developing in the first year of life. If the baby is not cyanotic then it is sometimes referred to as a "pink tet." Other symptoms include a heart murmur which may range from almost imperceptible to very loud, difficulty in feeding, failure to gain weight, retarded growth and physical development, dyspnea on exertion, clubbing of the fingers and toes, and polycythemia.

Children with tetralogy of Fallot may develop "tet spells". The precise mechanism of these episodes is in doubt, but presumably results from a transient increase in resistance to blood flow to the lungs with increased preferential flow of de-saturated blood to the body. Tet spells are characterized by a sudden, marked increase in cyanosis followed by syncope, and may result in hypoxic brain injury and death. Older children will often squat during a tet spell, which increases systemic vascular resistance and allows for a temporary reversal of the shunt.

Treatment

Complete surgical correction is now the most important and standard treatment of TOF. Several factors, such as old age, high hemoglobin level, pulmonary artery hypoplasia and a diminutive left ventricle, have been identified as risk factors for operative mortality in many previously published series. Palliative surgery includes the B-T shunt or Potts shunt, which constructs a communicating shunt between the systemic and pulmonary circulation. However, the outcome is poor and it is no longer standard treatment for TOF except when the patient's condition means they are not suitable for repair. It may be a bridge from symptom relief to total correction. Medication is used for symptom relief only.

Prognosis

Mortality is about 3% in children and 2.5% to 8.5% in adults. The survival rate of patients who receive repair surgery is about 86% at 32 years follow-up and 85% at 36 years follow up; survival rates of unoperated TOF patients older than 10 years is about 30%, older than 20 years 11%, older than 30 years 6% and older than 40 years only about 3%.

References

1. Topol Eric J. and Robert M. Califf. Textbook of cardiovascular medicine. Lippincott Williams & Wilkins, 2007.
2. Murphy JG, Gersh BJ, Mair DD, et al: Long-term outcome in patients undergoing surgical repair of tetralogy of Fallot. *N Engl J Med.* 1993; 329: 593-599.
3. Brickner ME, Hillis LD, Lange RA: Congenital heart disease in adults. Second of two parts. *N Engl J Med.* 2000; 342: 334-342.
4. Presbitero P, Prever SB, Contrafatto I, Morea M: As originally published in 1988: Results of total correction of tetralogy of Fallot performed in adults. *Ann Thorac Surg.* 1996; 61: 1870-1873.
5. Lien WP, Chen JJ, Chen JH, et al: Frequency of various congenital heart diseases in Chinese adults: Analysis of 926 consecutive patients over 13 years of age. *Am J Cardiol.* 1986; 57: 840-844.
6. Michael A Gatzoulis, Gary D Webb: *Diagnosis and Management of Adult Congenital Heart Disease*, 2003.
7. Fernando A Atik, Edmar Atik, Claudio R da Cunha: Longterm results of correction of tetralogy of Fallot in adulthood. *European Journal of Cardio-thoracic Surgery.* 2004; 250-255.
8. Wu Q: Indication and technique of total correction of tetralogy of Fallot in 228 patients. *Ann Thorac Surg* 1996; 61: 1769-1774.
9. Nollert G, Fischlein T, Bouterwek S, Bohmer C, Klinner W, Reichart B: Long-term survival in patients with repair of tetralogy of Fallot: 36-year follow-up of 490 survivors of the first year after surgical repair. *J Am Coll Cardiol.* 1997; 30: 1374-1383.